

DETECTING CELLS USING IMAGE SEGMENTATION OF THE CERVICAL CANCER IMAGES TAKEN FROM SCANNING ELECTRON MICROSCOPE

Sevcan AYTAÇ KORKMAZ

Firat University, Department of Electronic Technology, Elazığ- TURKEY

sevcanaytackorkmaz@gmail.com

Abstract: In this study, Matlab basic cell processes have implemented normal, benign and malign cervical cells taken from the Scanning Electron Microscope. These matlab basic cell process are binary gradient mask, dilated gradient mask, binary image with filled holes, cleared border, segmented, and outlined original. According to the results obtained after these operations, a difference has observed for malign image in images obtained from binary gradient mask, dilated gradient mask process. White space that is obtained after binary gradient mask and dilated gradient mask process applied to the malignant images were found to be much more than normal and benign images.

Keywords: Cervical Cancer, Matlab Basic Cell Process

Introduction

Cervical cancer is said that almost 288,000 deaths each year all over the world is the second most common cancer among women (Grubisic G, Klaric P, Jokanovic L, Soljacic Vranes H, Grbavac I, Bolanca I. 2009). cancer morbidity and mortality was determined 27 or earlier cancer can be reduced in the continuous case. In particular, such as the Pap smear for cervical cancer can be reduced. (Costa S, Negri G, Sideri M, Santini D, Martinelli G, Venturoli S, et al. 2007). Liquid-based cytology helps to reduce the percentage of 70-80 percent mortality of cervical cancer (Hanley KZ, Tadros TS, Briones AJ, Birdsong GG, Mosunjac MB.2009). The most important advantage of this test is simple and is the least invasive (Hoda RS, Colello C, Roddy M, Houser PM. 2005). These tests are effective and successful, although from what was expressed as the detection of preinvasive cervical lesions are located an average sensitivity of 55% (Saslow D, Runowicz CD, Solomon D, Moscicki AB, Smith RA, Eyre HJ, et al. 2002). invasive carcinoma detection accuracy is not perfect and show the different ranges of between 55% and 80% indifferent research (Benoit AG, Krepart GV, Lotocki RJ.1984). According to data provided by the American Cancer Society, about 3.6 million are classified as suspicious histological tests in the United States each year (Soost HJ, Lange HJ, Lehmacher W, Ruffing-Kullmann B.1991).

There are only 8% of women are preinvasive lesions and invasive carcinoma during tissue biopsy 0.4%. 95% of the true negatives and provide relatively high (Nanda K, McCrory DC, Myers ER, Bastian LA, Hasselblad V, Hickey JD, et al.2000). Therefore, a more accurate by eliminating the additional steps of test criteria biopsy and colposcopy, HPV DNA screening can reduce the cost and patient discomfort. In this study is a developed different solution using Scanning Electron Microscopy (SEM) images. In this study, Matlab basic cell processes have implemented normal, benign and malign cervical cells taken from the Scanning Electron Microscope. These matlab basic cell process are binary gradient mask, dilated gradient mask, binary image with filled holes, cleared border, segmented, and outlined original.

Materials and Methods

Image segmentation is the first step of the automatic picture pattern recognition and image analysis problems (Costa S, Negri G, Sideri M, Santini D, Martinelli G, Venturoli S, et al. 2007). Segmentation is the separation to constituent parts of image (Hoda RS, Colello C, Roddy M, Houser PM. 2005). The image segmentation process aiming grouped according to common characteristics of pixels, is intended to be a minimum of diversity in accordance with the criteria selected group obtained. In the literature, there are many segmentation algorithms. The most commonly used algorithms are algorithms such as Fuzzy c Means, K-means, such as Watershed. Proposed system used in this study is show in Figure 1. Segmentation used in this study was performed in stage 6.

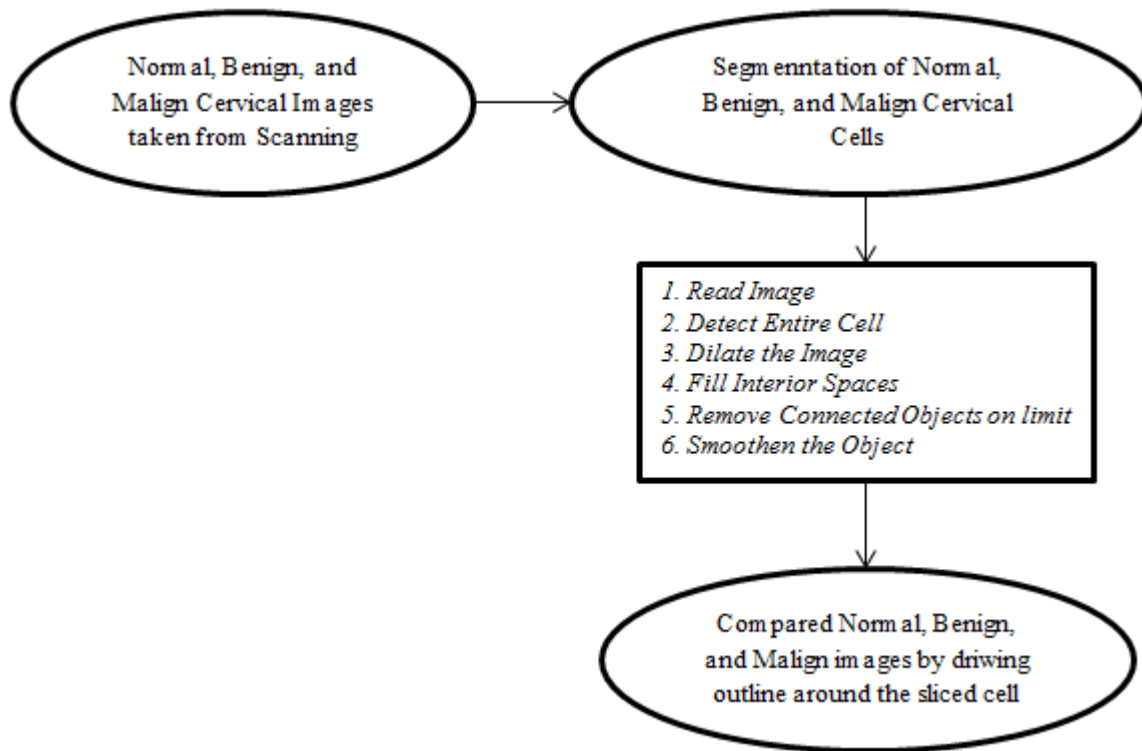


Figure 1. Proposed system in this study

Stage 1. Read Image

Read in the normal.tif, benign.tif, and malign.tif images, which are images of a cervical cancer cell (Mathworks. 1994-2016).

Stage 2. Detect Entire Cell

Cells are present in images. These images will detect cells. In other words, it is segmentation. Parts Separated image differs greatly in contrast to those in the background image. Changes in contrast can be determined by operators that calculate the gradient of an image. The gradient image can be calculated and a threshold can be implemented to create a binary mask containing the segmented cell. First, in this study is used edge and the Sobel operator to calculate the threshold value. Then, binary masks with threshold and edge cells are taken again (Mathworks. 1994-2016).

Stage 3. Dilate the Image

Binary gradient mask illustrates the route of high contrast in the image. These routes are not fairly that has strengthened the outline of the object of interest. Compared to the original image, the gradient of the line can be seen in the space surrounding the masked object. These linear gaps will lose if the Sobel image is expanded using linear structuring elements. The binary gradient mask is expanded using the vertical structuring element followed by the horizontal structuring element. The imdilate function is expanded the image (Mathworks. 1994-2016).

Stage 4. Fill Interior Spaces

It shows quite a nice gradient mask expanded cell lines, but they are still holes in the interior of the cell (Mathworks. 1994-2016).

Stage 5. Remove Connected Objects on limit

The cell shas been successfully segmented. Any objects that are ligated to the border of the image can be eliminated using the imclearlimit function. The connectivity in the limit function was set to 4 to eliminate diagonal connections (Mathworks. 1994-2016).

Stage 6. Smoothen the Object

Finally, the image is shown for a smoother more natural look of the piece object. Cervical cancer images are created the diamond structuring element using the strel function. An alternate method for demonstrate the sliced object would be settle an outline around the sliced cell. The outline is composed by the bwperim function (Mathworks. 1994-2016).

Results and Discussion

In this study is a developed different solution using Scanning Electron Microscopy (SEM) images. In this study, Matlab basic cell processes have implemented normal, benign and malign cervical cells taken from the Scanning Electron Microscope. These matlab basic cell process are binary gradient mask, dilated gradient mask, binary image with filled holes, cleared border, segmented, and outlined original. According to the results obtained after these operations, a difference has observed for malign image in images obtained from binary gradient mask, dilated gradient mask process. White space that is obtained after binary gradient mask and dilated gradient mask process applied to the malignant images were found to be much more than normal and benign images.



Figure 2. Normal cervical cell image



Figure 3. Grade converted image of the normal cervical cell

The larger the cell nucleus in Figure 3 was observed locally thickened.



Figure 4. Breaking of the edges with Sobel operator cell of normal cervical cell

In Figure 4 is remarkable the clutter of the edges. It shows the high-contrast areas of the image.



Figure 5. Obtaining of the enlarged edge

In addition to made processing in the above, by expanded of the edges in Figure 5 were found to be more dispersed.



Figure 6. Image which uncovered gaps in the internal portion of the image

In Figure 6, the edges are unloaded and revealed large gaps.



Figure 7. Limits cleaned image
In Figure 7, it is seen that the boundary portions becomes clear.



Figure 8. Segmented image

In Figure 8, the image has a more natural impression.

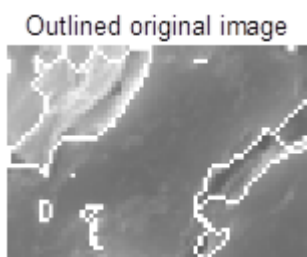


Figure 9. Outline determined image

In Figure 9 shows outline determined image




Figure 10. Benign cervical cell image




Figure 11. Grade converted image of the benign cervical cell

The larger the cell nucleus in Figure 11 was observed locally thickened.



Figure 12. Breaking of the edges with Sobel operator cell of malign cervical cell

In Figure 12 is remarkable the clutter of the edges. It shows the high-contrast areas of the image.



Figure 13. Obtaining of the enlarged edge

In addition to made processing in the above, by expanded of the edges in Figure 13 were found to be more dispersed.




Figure 14. Image which uncovered gaps in the internal portion of the image

In Figure 14, the edges are unloaded and revealed large gaps.




Figure 15. Limits cleaned image

In Figure 15, it is seen that the boundary portions becomes clear.



Figure 16. Segmented image

In Figure 16, the image has a more natural impression.



Figure 17. Outline determined image

In Figure 17 shows outline determined image.




Figure 18. Malign cervical cell image

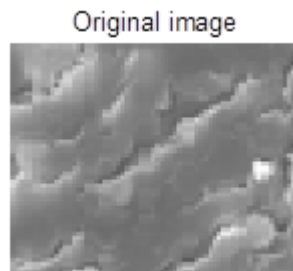


Figure 19. Grade converted image of the malign cervical cell

The larger the cell nucleus in Figure 19 was observed locally thickened.



Figure 20. Breaking of the edges with Sobel operator cell of malign cervical cell

In Figure 20 is remarkable the clutter of the edges. It shows the high-contrast areas of the image.



Figure 21. Obtaining of the enlarged edge

In addition to made processing in the above, by expanded of the edges in Figure 5 were found to be more dispersed.

binary image with filled holes



Figure 22. Image which uncovered gaps in the internal portion of the image

In Figure 22, the edges are unloaded and revealed large gaps.

Segmented image



Figure 24. Segmented image

In Figure 24, the image has a more natural impression.

Cleared border image



Figure 23. Limits cleaned image

In Figure 23, it is seen that the boundary portions becomes clear.

Outlined original image



Figure 25. Outline determined image

In Figure 25 shows outline determined image.

Conclusion

Image segmentation is the first step of the automatic picture pattern recognition and image analysis problems [2]. Segmentation is the separation to constituent parts of image [4,5,6]. The image segmentation process aiming grouped according to common characteristics of pixels, is intended to be a minimum of diversity in accordance with the criteria selected group obtained. In this study, Matlab basic cell processes have implemented normal, benign and malign cervical cells taken from the Scanning Electron Microscope. These matlab basic cell process are binary gradient mask, dilated gradient mask, binary image with filled holes, cleared border, segmented, and outlined original. According to the results obtained after these operations, a difference has observed for malign image in images obtained from binary gradient mask, dilated gradient mask process. White space that is obtained after binary gradient mask and dilated gradient mask process applied to the malignant images were found to be much more than normal and benign images.

Acknowledgements

Pathology samples of the cervical cancer cell images are given by Prof. Dr. İbrahim Hanifi ÖZERCAN. In addition, cervical SEM images are taken from Scanning Electron Microscope laboratory in the Firat University with the help of the Prof. Dr. Fahrettin YAKUPHANOĞLU.

References

- Grubisic G, Klaric P, Jokanovic L, Soljadic Vranes H, Grbavac I, Bolanca I. (2009). *Diagnostic approach for precancerous and early invasive cancerous lesions of the uterine cervix*. Coll Antropol;33:1431-6.
- Costa S, Negri G, Sideri M, Santini D, Martinelli G, Venturoli S, et al.(2007). *Human papillomavirus (HPV) test and PAP smear as predictors of outcome in conservatively treated adenocarcinoma in situ (AIS) of the uterine cervix*. Gynecol Oncol;106:170-6.
- Hanley KZ, Tadros TS, Briones AJ, Birdsong GG, Mosunjac MB.(2009). *Hematologic malignancies of the female genital tract diagnosed on liquid-based Pap test: Cytomorphologic features and review of differential diagnoses*. Diagn Cytopathol;37:61-7.

- Hoda RS, Colello C, Roddy M, Houser PM. (2005). "Fruiting body" of *Aspergillus* species in a routine cervico-vaginal smear (Pap test). *Diagn Cytopathol* ;33:244-5.
- Saslow D, Runowicz CD, Solomon D, Moscicki AB, Smith RA, Eyre HJ, et al. (2002). *American Cancer Society guideline for the early detection of cervical neoplasia and cancer*. *CA Cancer J Clin*;52:342-62.
- Benoit AG, Krepart GV, Lotocki RJ. (1984). *Results of prior cytologic screening in patients with a diagnosis of Stage I carcinoma of the cervix*. *Am J Obstet Gynecol*;148:690-4.
- Soost HJ, Lange HJ, Lehmacher W, Ruffing-Kullmann B.(1991). *The validation of cervical cytology. Sensitivity, specificity and predictive values*. *Acta Cytol*;35:8-14.
- Nanda K, McCrory DC, Myers ER, Bastian LA, Hasselblad V, Hickey JD, et al. (2000). Accuracy of the Papanicolaou test in screening for and follow-up of cervical cytologic abnormalities: a systematic review. *Ann Intern Med* ;132:810-9.
- Mathworks. (1994-2016). Detecting a Cell Using Image Segmentation